

Class II restoration of a primary molar

Procedure/Study by

Dr. Marina Papachroni - Patras - Greece

myClipjunior



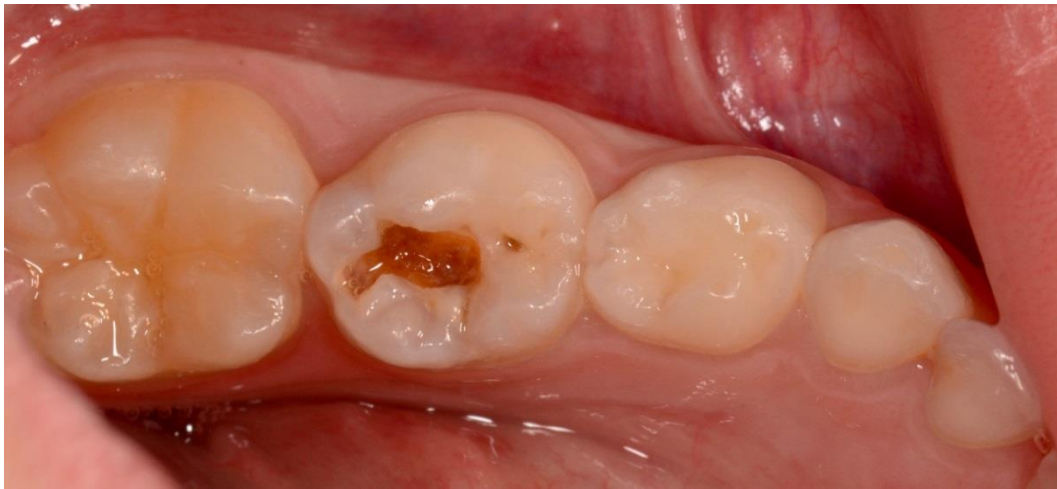Marina Papachroni graduated in 1995 from dental school at the University of Athens. She completed a three-year post-graduate program where she received her pediatric dentistry specialization certificate in 1999 and a two-year master's degree in dental materials in 2001 from the same university. Thereafter, she has attended numerous congresses, courses and continuing education programs. She is the Treasurer of the Board of the Hellenic Academy of Clinical Dentistry and a member of the Hellenic Society of Pediatric Dentistry, European Academy of Pediatric Dentistry and International Association of Pediatric Dentistry. Lately, she is lecturing on Bioactive Materials, Restorative Pediatric Dentistry and Pulp Therapy of Primary teeth. The current focus of the clinical research is Bioactive Restorative Materials. Dr. Papachroni runs her private practice in Patras, Greece, with emphasis on aesthetic and microscopic pediatric dentistry.

Case Report

The young patient came to our attention for a periodic control. The preliminary analysis revealed a class II carious lesion on molar 84, distal and a class I carious lesion on molar 85.

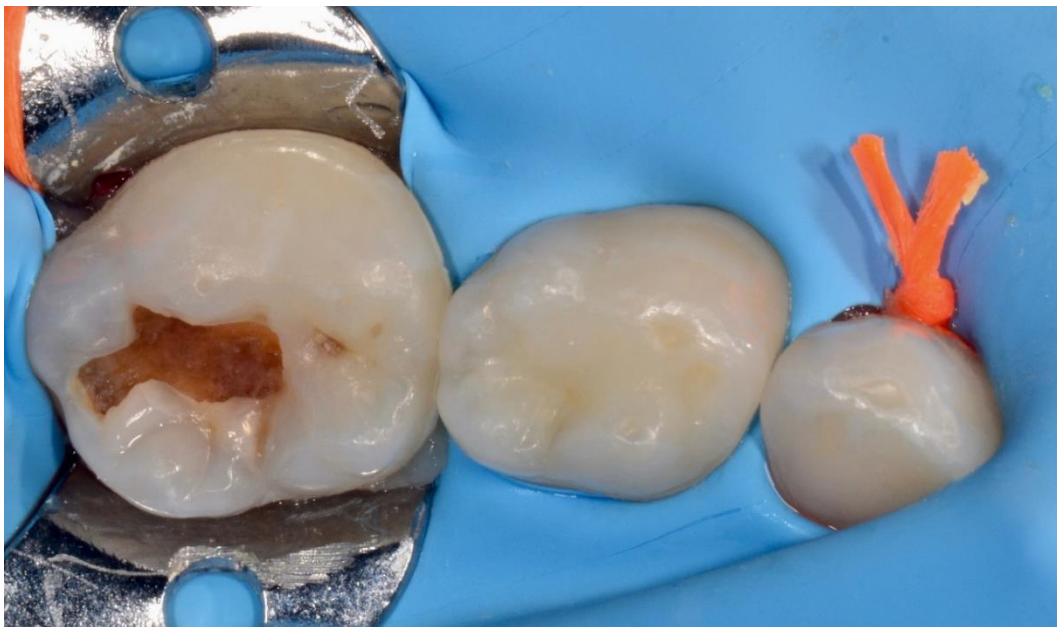Because of the reduced crown height, we decided to improve the ring stability using the myClip Junior in combination with the provided extremities myTines Junior and proceed with a direct composite restoration of the occlusal and distal interproximal morphologies.

The following images study shows the step-by-step restoration procedure using Polydentia myJunior kit.



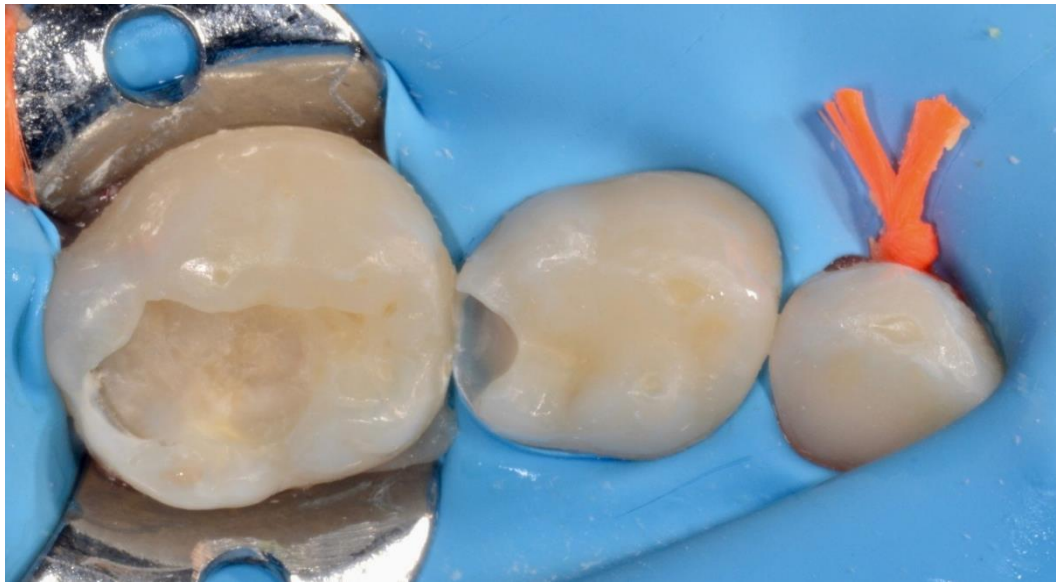
01

Pre-operative situation showing a class I carious lesions on primary molar 85 and a class II on 84.

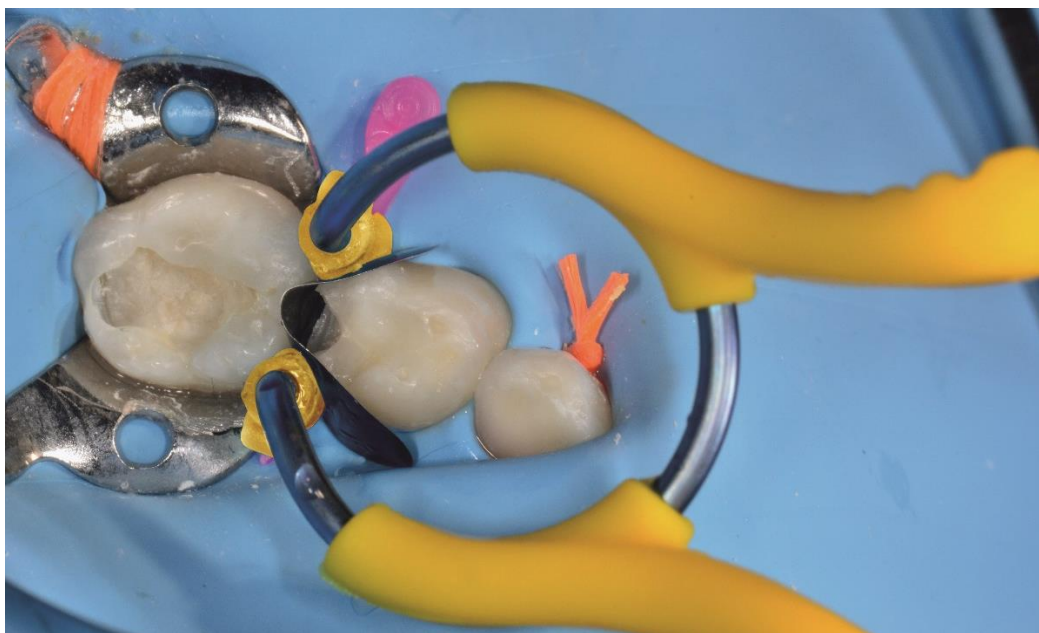


02

The view after rubber dam isolation.

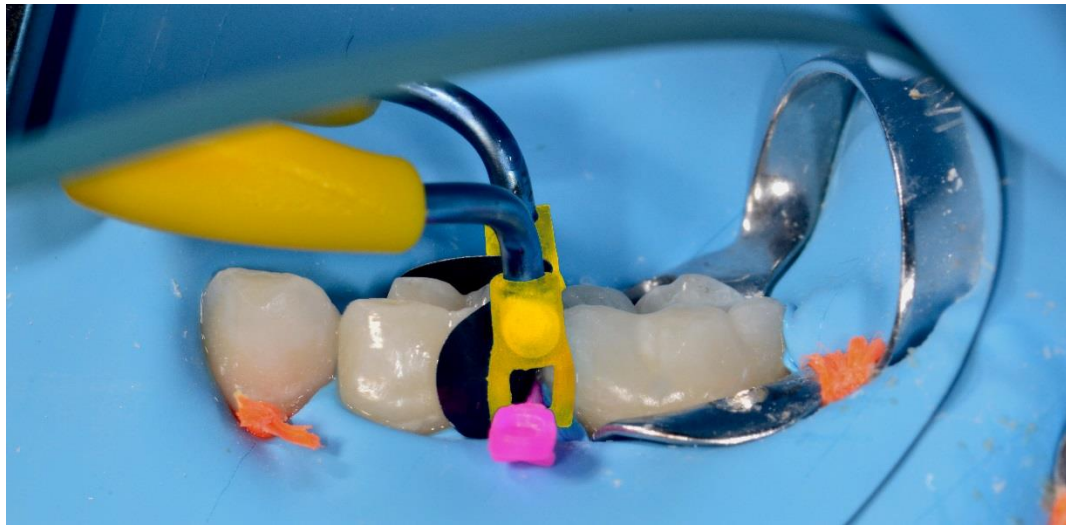

- 03 The clinical situation after the preparation of the cavity, cleaned with air abrasion and disinfected.



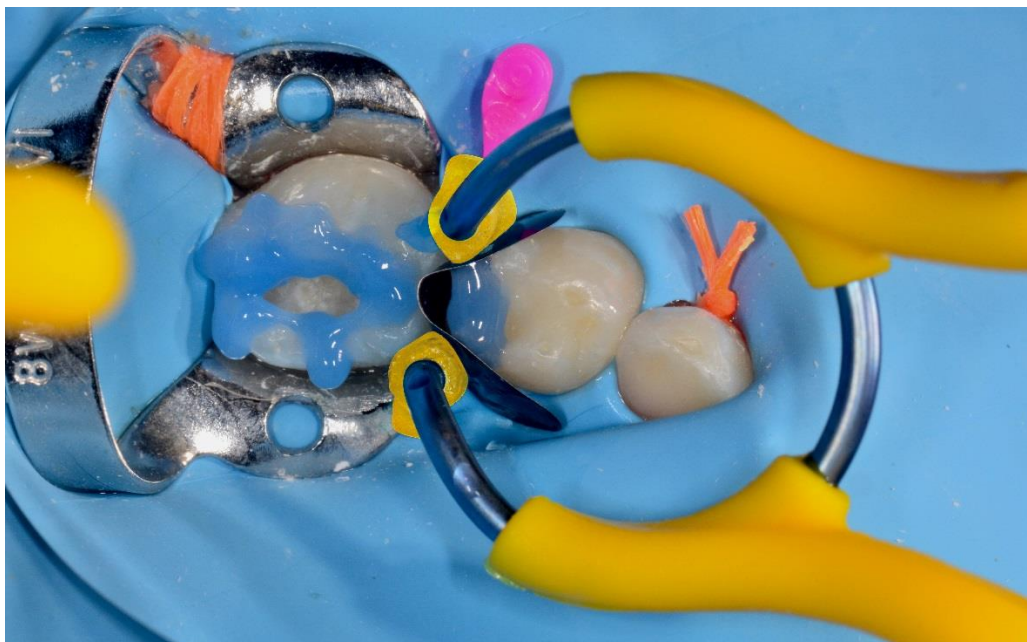
0
4

Primary molar 84 equipped with myClip Junior ring, LumiContrast matrix and myWedge. myClip Junior in combination with myTines Junior and myWedge provides a reliable and stable solution for the restoration of small primary teeth. A common problem when dealing with primary dentitions is the difficulty to completely insert a wedge because of the small cervical spaces. The hollow V-shape of the myWedges allow them to compress, allowing an easy placement and improved matrix adaption to the cervical walls.



05

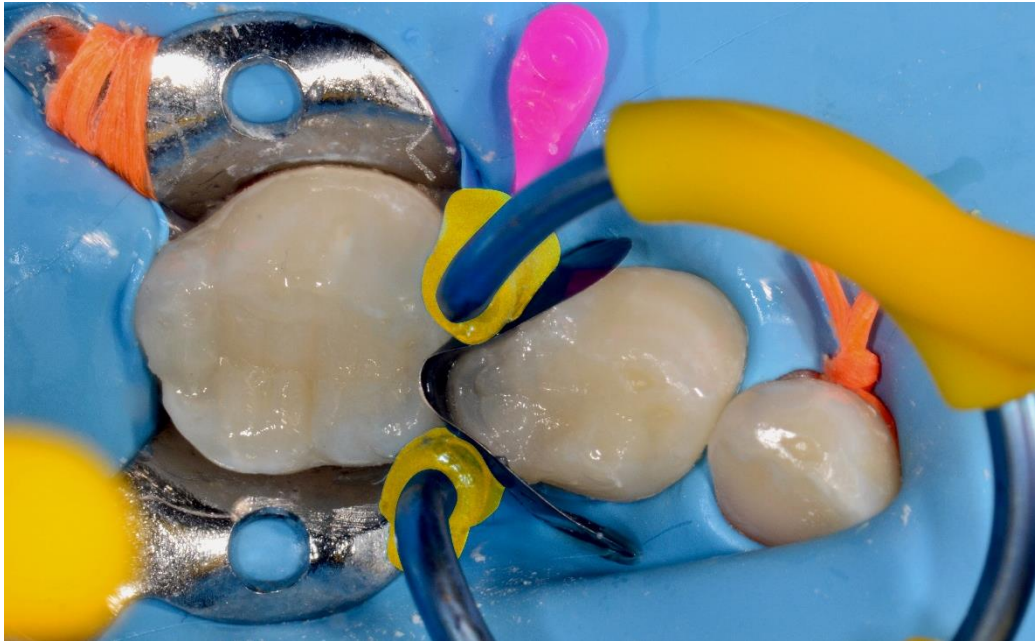Labial view of the clinical situation; the geometry of the myTines Junior carefully embraces the wedge preventing the spring off effect of the ring even in case of younger patient with very low dental crown height.



06

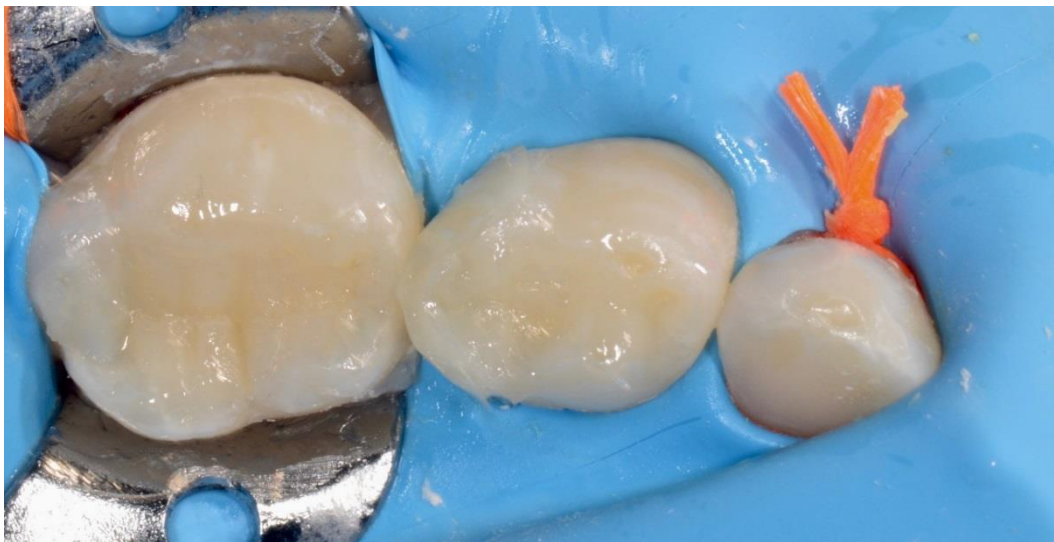Enamel margins have been etched using a standard 35% phosphoric acid solution.

07

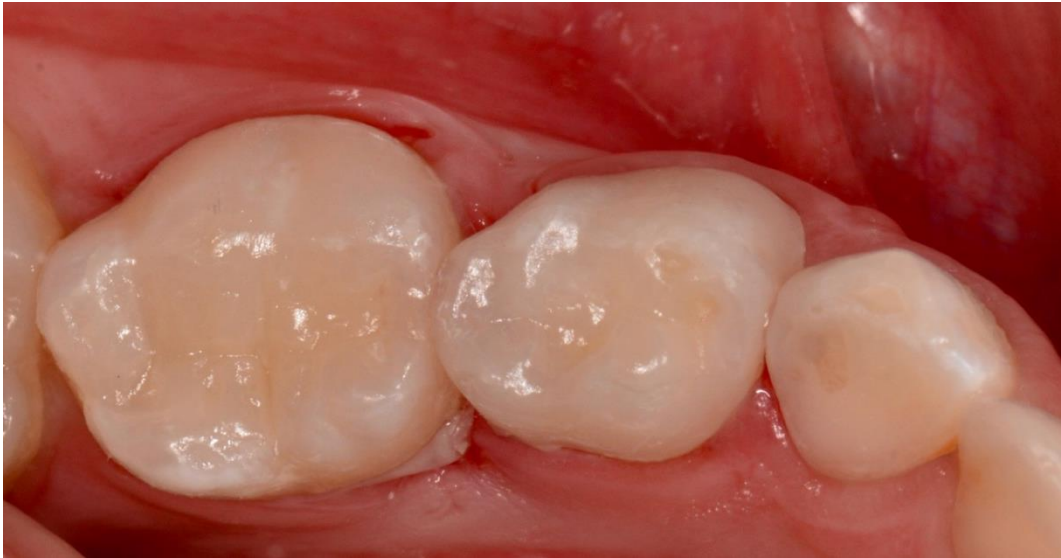

Both cavities were filled with composite resin. We then modelled the occlusal surfaces, and light cured the filling material.

08



myClip Junior, myWedge and LumiContrast matrix were removed before proceeding with finishing and polishing procedures.



09 Final image of the restoration immediately after rubber dam removal

Conclusion

MyClip Junior ring is designed especially for primary and young permanent teeth. Its accurate adaptation to the interproximal areas simplifies the finishing procedures. In case of younger patients, the extremities myTines Junior make the ring more stable and easier to adapt, preventing the spring off effect. Also, it is obvious that with myClip Junior ring we got better contact points. I regard myClip Junior as an optimal solution for paediatric treatments. It allowed me to achieve an ideal restoration with less efforts and with considerable chair-time savings.