Procedure/Study by

Dr Marina Papachroni

Patras - Greece

# Class II direct composite restoration on first premolar with myClip Junior paediatric sectional matrix ring and QuickmatFLEX sectional matrix

Marina Papachroni graduated in 1995 from dental school at the University of Athens. She completed a three-year post-graduate program where she received her pediatric dentistry specialisation certificate in 1999 and a two-year master's degree in dental materials in 2001 from the same university. Thereafter, she has attended numerous congresses, courses, and continuing education programs. She is the Treasurer of the Board of the Hellenic Academy of Clinical Dentistry and a member of the Hellenic Society of Pediatric Dentistry, the European Academy of Pediatric Dentistry, and the International Association of Pediatric Dentistry.
Lately, she lectures on Bioactive Materials, Restorative Pediatric Dentistry and Pulp Therapy of Primary teeth. The current focus of clinical research is Bioactive Restorative Materials. Dr Papachroni runs her private practice in Patras, Greece, emphasising aesthetic and microscopic pediatric dentistry.

## Case Report

A male teenager came to our office feeling pain in the upper left quadrant. We proceeded with a Class II restoration of the first premolar without removing brackets. The following images show the step-by-step direct composite restoration procedure using the premolar sectional matrix QuickmatFLEX in combination with the paediatric sectional matrix ring myClip junior.

01

Preoperative situation. The carious lesion is located on the first premolar right behind the orthodontic wire.

02

Preoperative occlusal view after rubber dam isolation. We employed a split dam technique because of the orthodontic treatment.

03

The cavity after cleaning and disinfection.

04

The major problem, in this case, was the adaptation of a matrix. We used the sectional matrix QuickmatFLEX (Polydentia, developed with StyleItaliano) because it is very thin (0.03 mm) and easy to handle.
The innovative material of QuickmatFLEX (Polydentia) gives this matrix the ability to resist deformation as it features high elastic resilience, springing back to its original shape.
Therefore, the specific matrix allowed us to enter this small interdental space, under the orthodontic wire, without losing its anatomical convex shape.

We employed myClip Junior (Polydentia) customised with one silicone tube at the palatal side to adapt the matrix to the tooth.
On the buccal side, due to the orthodontic brackets and wire, we secured and adapted the sectional matrix with the help of a wooden wedge (Wood Wedge S, Polydentia).

05

The clinical situation after the restoration and before removing the sectional matrix system.

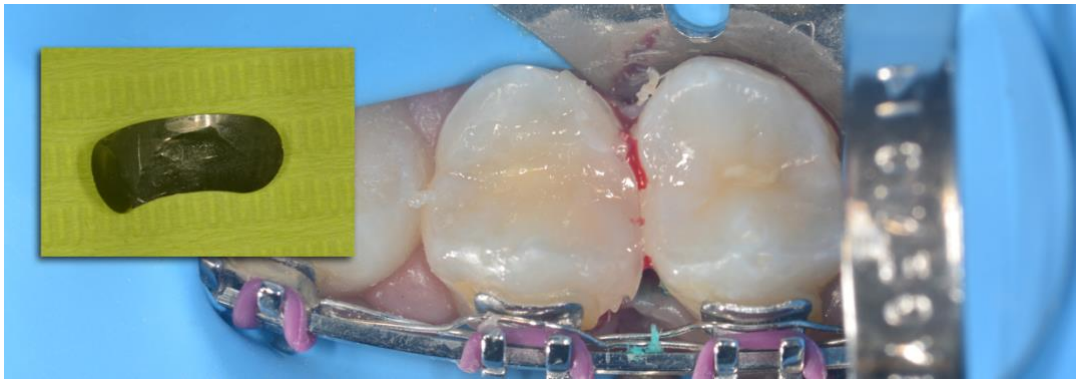

06

Occlusal view of the direct composite restoration immediately after removing the sectional matrix system. The perfect adaptation of the matrix at the buccal and palatal margins of the restoration produced fewer flashes and thus reduced the finishing time. The small photo shows the minimal deformation of the matrix after the procedure.

07

Final restoration without rubber dam. Notice the tight contact point between premolars.
Without QuickmatFLEX, the specific restoration would have not been possible to achieve. Thanks to its technical characteristics, the sectional matrix QuickmatFLEX is easy to handle and adapt in the narrow interproximal space under the orthodontic wire.

## Conclusion

This clinical case demonstrates how new restorative materials encourage us to explore previously considered complicated possibilities, if not impossible.

Thanks to the resilient and deformation-resistant properties of QuickmatFLEx (sectional matrix, Polydentia) and myClip Junior (peadiatric sectional matrix ring, Polydentia), we performed a Class II direct restoration on a tooth under orthodontic treatment without having to remove wires or brackets.
These restorative solutions allowed us to work more efficiently and save time at the chairside.