

Class II adjacent cavities on 1st and 2nd molars

Procedure/Study by

Dr. David Gerdolle, Montreux - Switzerland

QuickmatFIT

myRing Forte

myWedges



Dr. Gerdolle graduated from the Faculty of Dentistry of Nancy University in 1993. Since 1995, he has obtained postgraduate qualifications in Prosthodontics, oral biology, implantology, Forensic Medicine and Forensic Dentistry.

Between 1996 and 2005 he lectured at the Nancy School of Dentistry, and still plays a very active role as the head of postgraduate training in adhesive and biomimetic dentistry at the University of Paris, as well as being a Certified Instructor of the Academy of Biomimetic Dentistry.

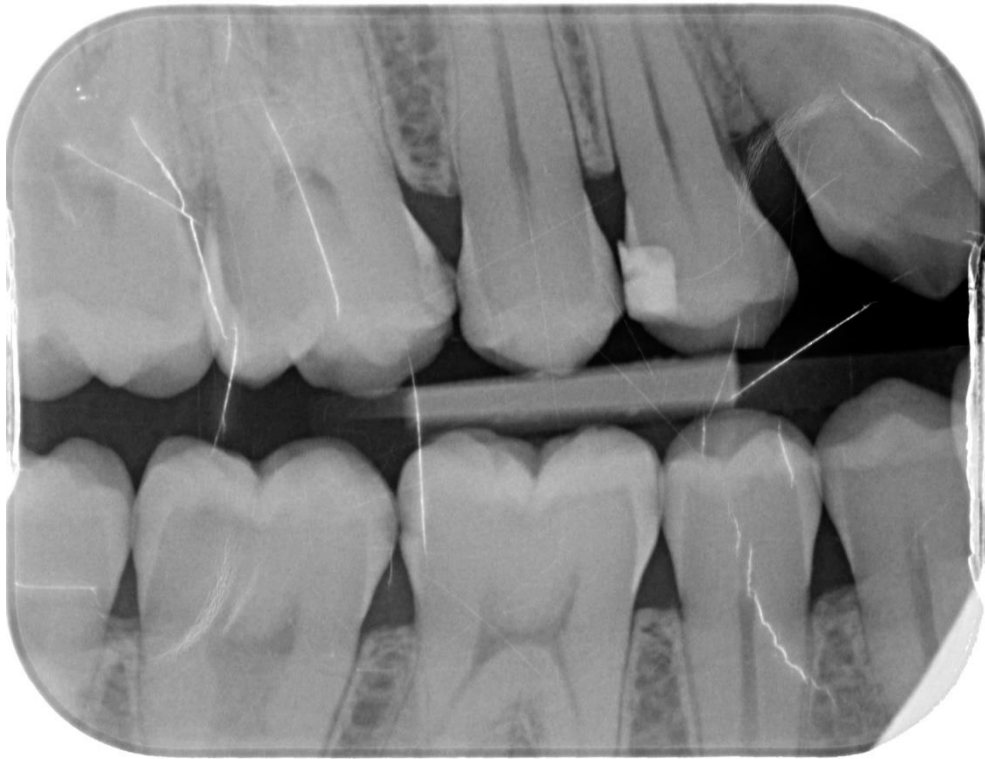Dr. Gerdolle has practiced privately in Switzerland since 2005, focusing on conservative and minimally-invasive dentistry.

In addition to his academic and practical work, Dr. Gerdolle is the author of 60 national and international scientific publications and of more than 250 lectures in seminars, congresses and hands-on courses in the field of restorative dentistry.

Case Report

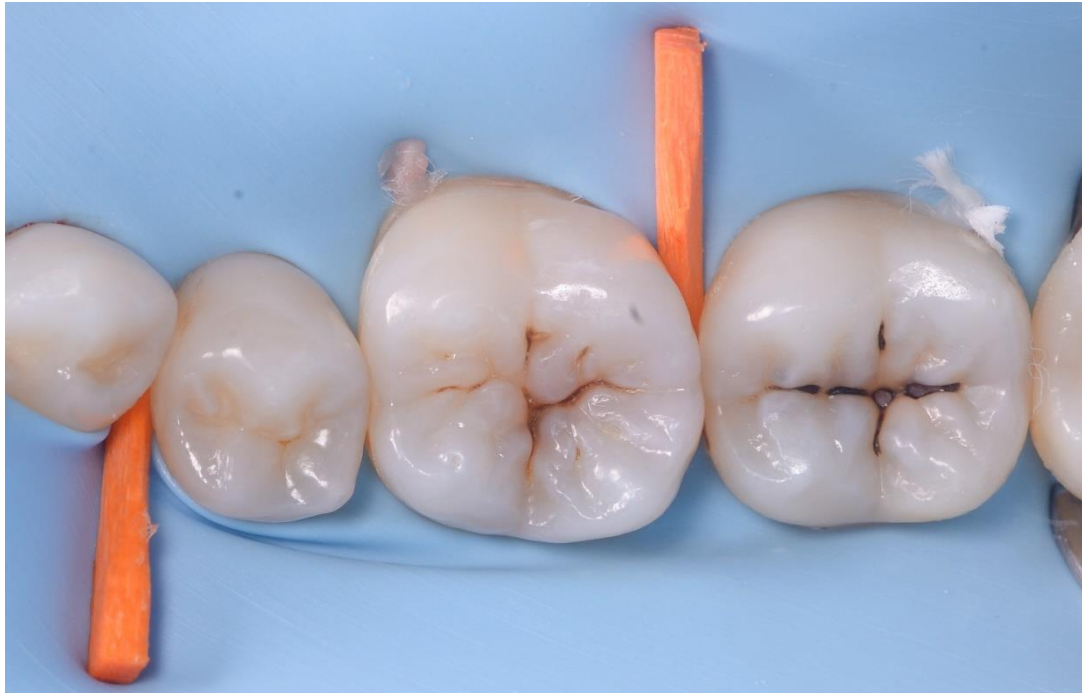A 28-year-old female patient, without any systemic medical conditions presented with a carious lesion affecting both molar 46D and 47M.

The following case illustrates the direct composite restoration of the lesion using the Polydentia QuickmatFIT anatomical sectional matrices in combination with myRing Forte and myWedge plastic v-shaped wedges.



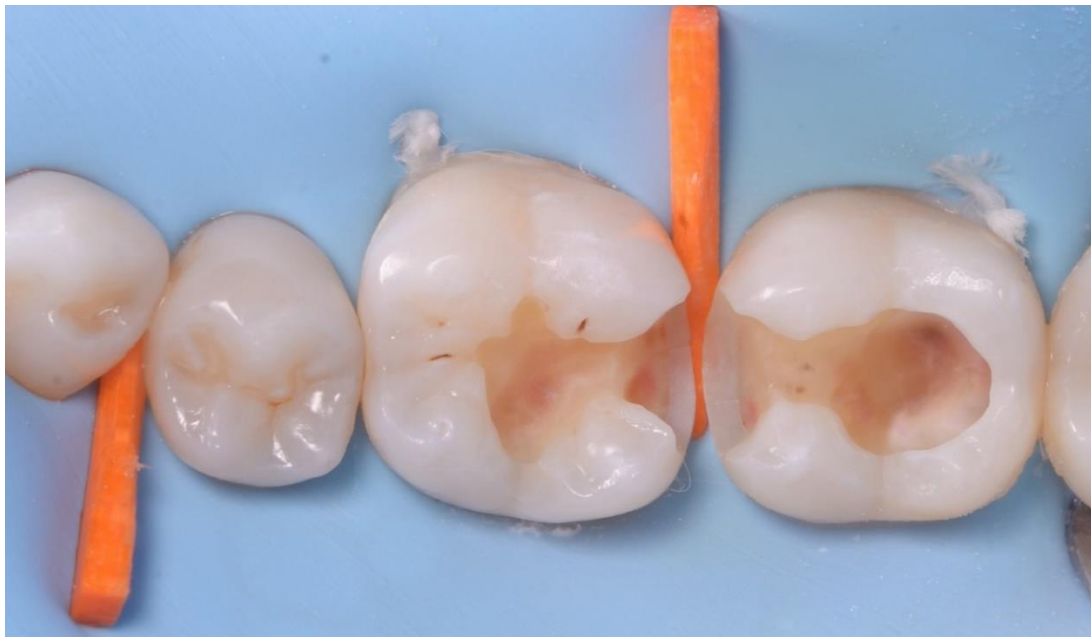01

Pre-operative x-ray showing a carious lesion affecting both molar 46D and 47M



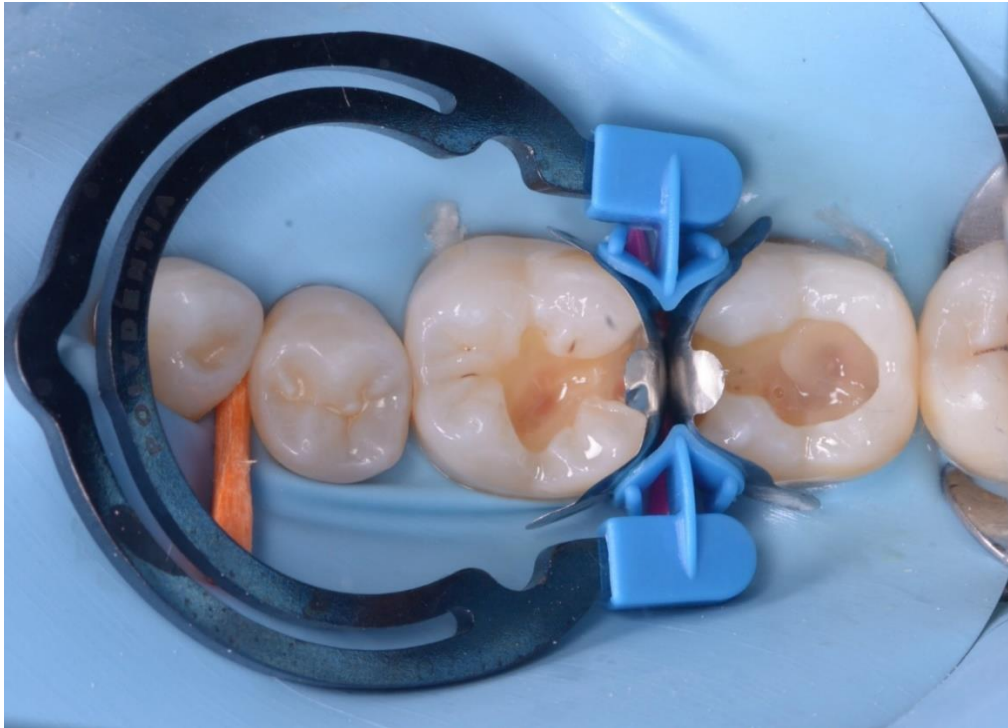
02

Pre-operative view of quadrant 4 under isolation; pre-wedging was carried out using a wooden wedge to facilitate the placement of the sectional matrices.



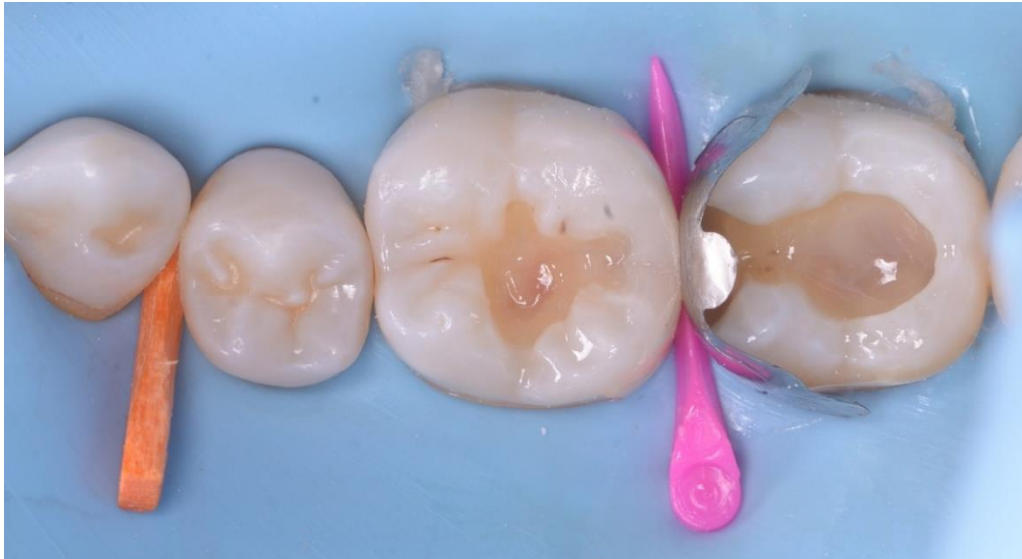03

The cavities after caries removal, cleaning and disinfection.



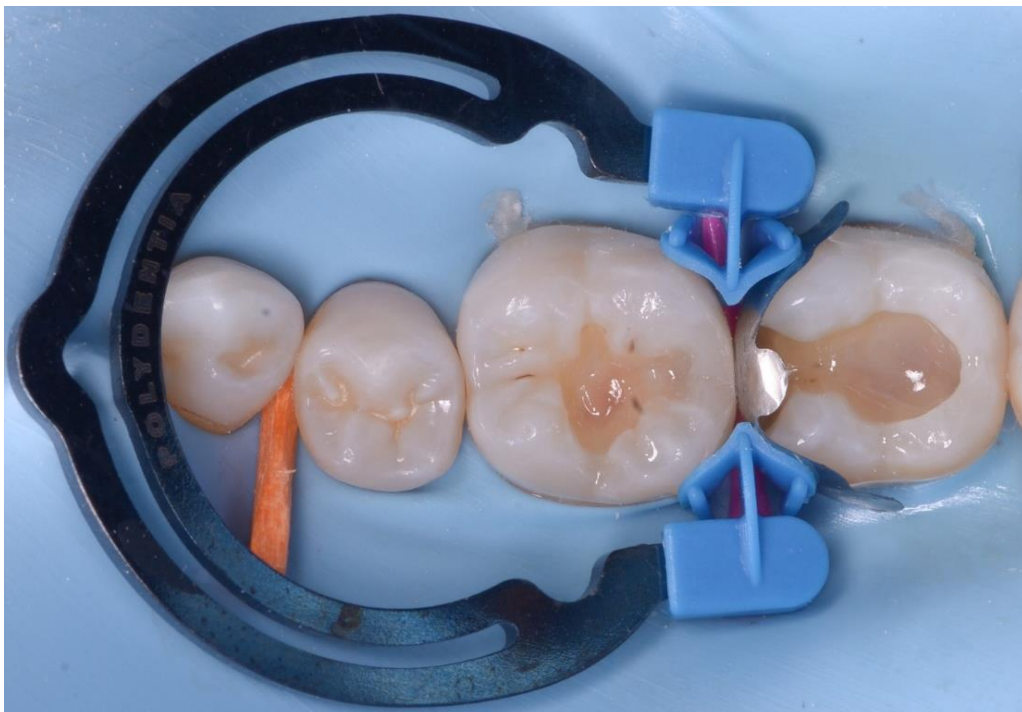04

Matrixing: two QuickmatFIT molar matrices were placed on 46D and 47M to seal the cavities. For effective tooth separation, myRing Forte was positioned before proceeding with the proximal walls restorations. The anatomical contouring of the QuickmatFIT matrices results in two main benefits for the dentist: increased rigidity of the matrix itself, making it easier to position, and improved adaptation to tooth morphology, requiring less finishing of the composite filling.



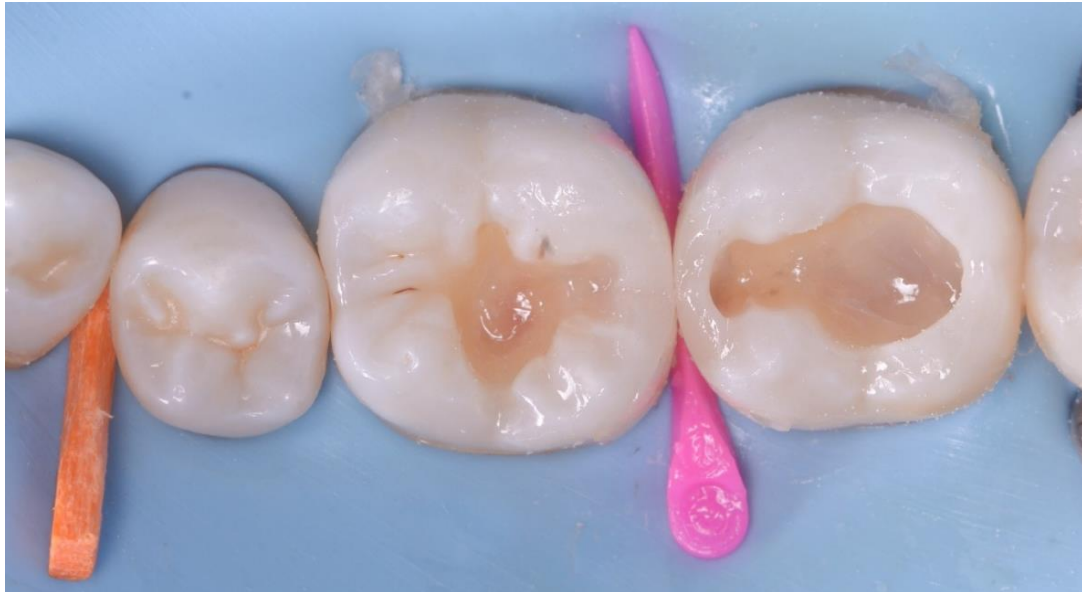05

Once the distal surface of Molar 46 had been restored, the myRing Forte and QuickmatFIT sectional matrix were removed.



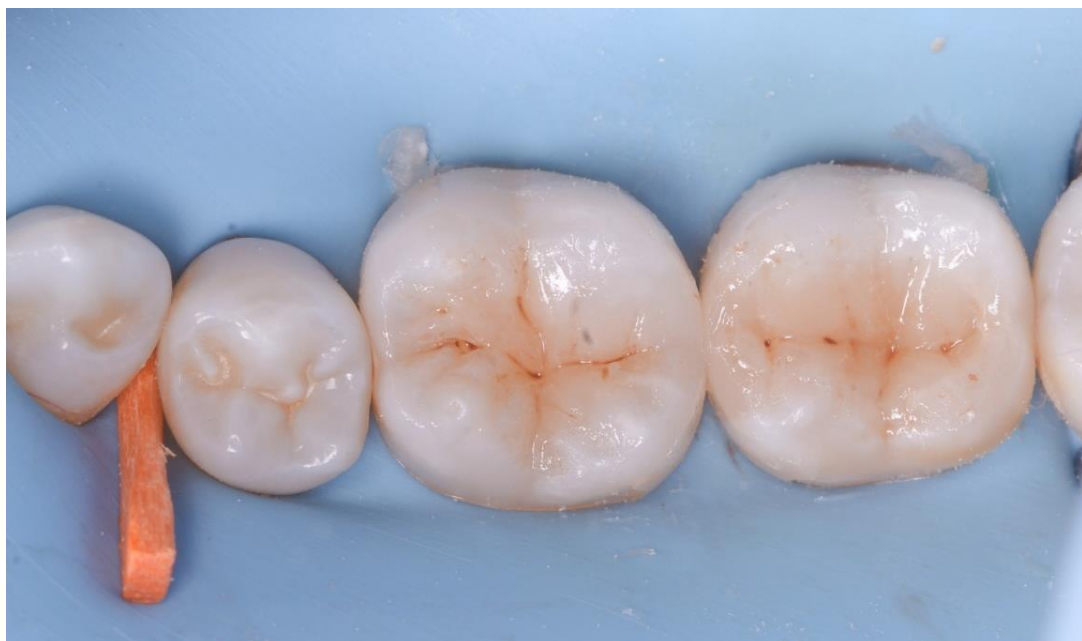06

The myRing Forte was then repositioned for the restoration of the mesial wall of Molar 47.



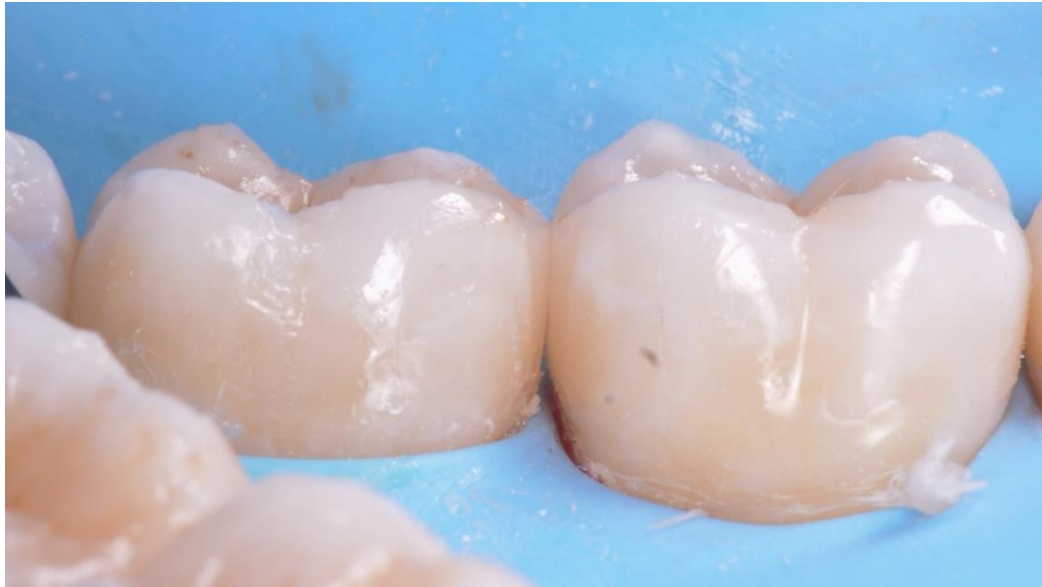07

The clinical situation after proximal wall restoration.



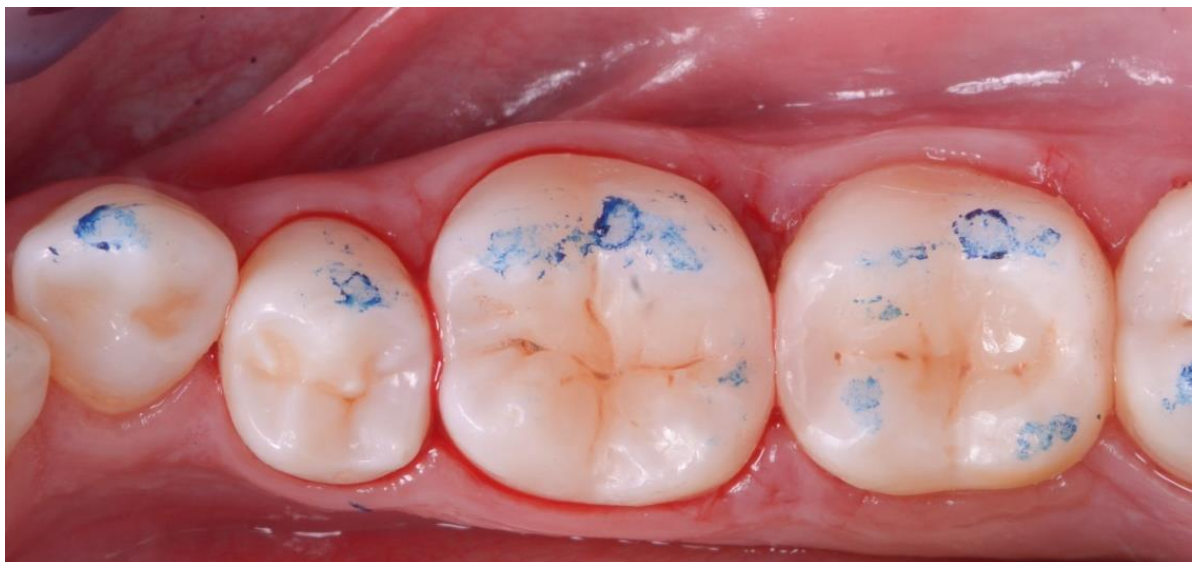08

Modelling of the occlusal surfaces; a small amount of brown pigments were used to reproduce stain.



09

Side view of the clinical situation before finishing and polishing, showing the accurate morphology reconstruction afforded by the QuickmatFIT matrices.



10

Post-op view of the restoration after finishing and polishing and an occlusal check.

Conclusion

QuickmatFIT sectional matrices from Polydentia combine a high-rigidity alloy with a unique three-dimensional profile, providing an easy solution to a number of difficult clinical situations. When used in combination with myRing Forte, the result is a reconstruction with an accurate and natural morphology, that reduces the time required for the finishing steps.